

Assessment of wound healing following electrical stimulation with Accel-Heal[®]

Electrical stimulation is the use of an electrical current to transfer energy to a wound. When the body's endogenous bioelectric system fails and cannot contribute to repair processes, therapeutic levels of electrical current are delivered into the wound tissue from an external source. Many chronic wounds heal slowly, do not heal, or worsen, despite the best efforts of care givers to promote tissue repair (Posnett and Franks, 2008). Synapse Accel-Heal[®] is a registered class IIA medical device, which uses a specific proprietary sequence of micro-current electrical pulses designed to interact with biological processes that have become dormant within a chronic non-healing wound.

David Chapman-Jones, Steve Young, Martin Tadej

KEY WORDS

Accel-Heal[®]
Electrical stimulation
Chronic wounds
Clinical evaluation

Electrical stimulation (ES) therapy involves the transfer of an electric current to the skin surface adjacent to the wound edge via two electrodes. The net effect of this current delivery is to create a flow of ions through the wound tissue. This type of therapy has been around for many years in one form or another; for example, galvanic stimulation. Studies have reported its beneficial effects in promoting wound healing (Kloth and McCulloch, 1996; Karba et al, 1997; Sussman and Byl, 1998; Bayat et al, 2006). The effect that this therapy has on wounds cannot be attributed to one mechanism of action, as several actions have been identified,

including galvanotaxic effects where different cell types are attracted to different electrodes depending upon their relative charge (Balakatounis and Angoules, 2008; Rosenblum, 2009). One of the reasons for this is the interruption of the biological flow of electricity that controls cell behaviour; cell communication and the transfer of molecules between cells.

Direct stimulatory effects on cells, such as fibroblasts, have been noted in terms of cell number and collagen synthesis (Jaffe and Vanable, 1984; Bogie et al, 2000; Kloth, 2002).

Electrical stimulation accelerates wound healing by increasing capillary density and perfusion, improving wound oxygenation and encouraging granulation and fibroblast activity (Junger et al, 1997; Gagnier et al, 1988; Peters et al, 1998). Neutrophil, macrophage, fibroblast, and epidermal cells involved in wound repair carry either a positive or negative charge. When these cells are needed to contribute to autolysis, granulation tissue formation, anti-inflammatory activities, or epidermal resurfacing, ES may facilitate galvanotaxic attraction of these cells into the wound tissues, thereby accelerating healing.

Research demonstrates that the application of ES for wound healing increases the rate of healing by more than 50% (Junger et al, 1997; Gagnier et

al, 1988; Peters et al, 1998). In addition to stimulating wounds directly, there is evidence that ES has an antibacterial effect as, although the exact mechanism is unclear, it appears to inhibit the reproduction of bacteria (Yarkony, 1994). There is also evidence that electrical stimulation can increase blood flow in wounds (Gagnier et al, 1988; Peters et al, 1998), and has been shown to reduce oedema (Mohr et al, 1987; Reed 1988). This is important as oedema can significantly delay wound healing, causing increased pain and tissue fibrosis and decreasing mobility and formation of adhesions (Mohr et al, 1987; Reed, 1988).

Wound assessment

There are two main techniques to assess wounds — invasive and non-invasive. Invasive techniques involving biopsy can yield quantitative results. However, the tissue has to be destroyed to obtain the data and can contain artefacts (i.e. other tissues that may contaminate the tissue sample, for example, fibrous scar tissue) produced by the preparation technique. Non-invasive methods do not destroy tissue, although the results tend to be more subjective. This is demonstrated in one of the most common forms of wound assessment, wound area measurement, where digital photographs are taken of the wound and the area is calculated from the image using a computer. Error can occur when deciding where the wound edge is and so precise calibration of the photograph

David Chapman-Jones is Director of Medicine and Science, Synapse Microcurrent Ltd, Westerham; Steve Young is a Freelance Clinical Scientist, Cambridge; Martin Tadej is Tissue Viability Nurse Specialist, Tissue Viability Consultancy Service (TVCS), Eastbourne

is essential. Another weakness in this form of assessment is that it only informs you about the wound surface, not what is happening at the wound bed or in the surrounding tissues (Young and Ballard, 2001).

To date, evaluation of wounds and their progression to healing has tended to rely on findings from physical examination which are, at best, subjective. However, high frequency diagnostic ultrasound is a non-invasive method which allows clinicians to obtain high-resolution images of the wound bed (Yarkony, 1994 ; Chen et al, 2001; Mirpuri and Young, 2001; Young et al, 2001; Kerr et al, 2006; Quintavalle et al, 2006; Young et al, 2008). This is a relatively new, increasingly important diagnostic tool.

The recent introduction of technologically advanced ultrasound equipment using 20MHz transducers has enabled ultrasound to be used on wounds. This has opened up the lower structures to examination without the need for biopsy, providing accurate, verifiable and statistical data related to healing. It is easy to use, completely safe, and gives important diagnostic information (Yarkony, 1994 ; Chen et al, 2001; Mirpuri and Young, 2001; Young et al, 2001; Kerr et al, 2006; Quintavalle et al, 2006; Young et al, 2008). Wounds can now be studied clearly, detailing the three layers forming the normal skin (epidermis, dermis and subcutaneous tissues) and demonstrating changes that occur during healing.

This technique allows clinicians to study the wound bed beneath the surface, providing the opportunity to see changes occurring before they become clinically evident, thus giving an early indication as to whether the wound is deteriorating or improving.

Such a diagnostic tool is helpful in the evaluation of new therapies and was used in the assessment of a new electrical-based treatment delivered by Accel-Heal® (Synapse), a class IIA medical device.

This paper evaluates the clinical and cost-effectiveness of wound healing

following the application of Accel-Heal, which delivers a proprietary sequence of low intensity electrical current on complicated venous leg ulcer (VLU) wounds, clinically classified as non-healing.

Method

Twenty two (n=22) subjects with chronic non-healing VLUs were recruited from patients referred to a specialist wound healing clinic, Tissue Viability Consultancy Service (TVCS), Eastbourne for the evaluation. A prospective observational method was used. Only subjects with non-healing wounds were enrolled. The inclusion criteria were any subject with a VLU wound that did not have an ankle brachial pressure index (ABPI) below 0.8. Exclusion criteria were those refusing consent, moribund patients with an ABPI >0.8, or any pathology that would be unlikely to respond to treatment (rheumatoid arthritis, *pyoderma gangrenosum*, etc).

The following protocol was followed.

Visit one

- ▶ Subjects were identified and consent was obtained
- ▶ The wound was photographed and the area measured at TVCS
- ▶ An ultrasound scan was carried out on the wound and surrounding intact periwound skin to establish a baseline
- ▶ Each patient's current wound care regimen continued unchanged. In general, this was 4-layer compression bandaging
- ▶ Levels of pain were assessed using a 0–10 scale, where 0 equalled no pain and 10 was unbearable pain
- ▶ Exudate levels were assessed using a 0–10 scale, where a score of 10 indicated that the dressing needed changing daily due to exudate loss, and 0 equated to no dressing change was required.

Visit two: 28 days after the initial baseline assessment

- ▶ Wounds were photographed and measured. From this information it was possible to establish if the wound was continuing to be non-healing. If the wound had shown progress towards healing from visit

one, the subject was excluded from the evaluation

- ▶ If the wound had not healed/ progressed from visit one, the subject continued on the evaluation
- ▶ Patients continuing on the evaluation were started on the Accel-Heal treatment. This was used in addition to the standard therapy for VLU, compression bandaging (O'Meara et al, 2009). Electrical stimulation was only applied for a 12-day period to 'kick start' the healing process. A natural part of healing is that as the wound heals, the current of injury is also reduced, and to continue stimulation may not be necessary
- ▶ Pain and exudate levels were re-assessed in comparison to visit one.

Visit three: 12 days after visit two. Accel-Heal treatment was stopped at this point

- ▶ Wounds were photographed, measured and scanned
- ▶ Pain and exudate levels were re-assessed in comparison to visit two.

Visit four: 10 days after visit three

- ▶ The same assessment criteria were followed as per visits two and three.

Visit five: 90 days follow-up

- ▶ In between the formal assessment visits, patients were seen for dressing changes every 48 to 72 hours. Each patient saw the same nurse who maintained the original care regimen to ensure that the data collected was as objective as possible, given human error related to visual inspection and palpation of the skin. This also ensured that any changes were not due to other alterations in the patient's care.

Accel-Heal™ electrical stimulation device

The Accel-Heal device delivers a pulsed microcurrent over a programmed 48-hour period. It consists of two electrode pads (*Figure 1a*) containing a moist conductive medium, which are placed either side of the wound on the intact skin a few centimetres from the wound edge. These pads are connected to the self-contained pre-programmed device (*Figure 1b*), which is attached externally to compression bandages.

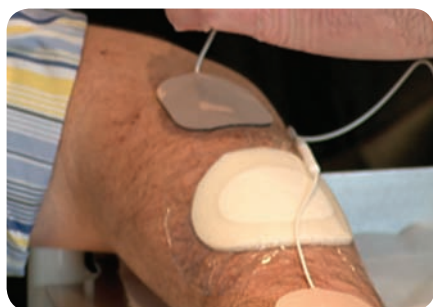

Figure 1a. The electrodes.

The aim of treatment is to cause an effect on a number of levels. Primarily, it is designed to facilitate molecular transfer between cells to bring about homeostasis to an area that is biochemically disrupted as a result of illness or injury, for example, in a chronic non-healing wound. In a similar way to a drug dosage targeting specific cell function, a specific amperage, polarity and pulse rate is used that synchronises with specific parameters of the cell type, such as dermocytes, to promote/augment the restoration of targeted processes, for example, cell to cell molecular transfer, particularly calcium by establishing electrical gradients across the cell membrane to promote membrane permeability. Accel-Heal uses a series of patented pre-set programmes in a sealed unit which run for a continuous 48-hour period. The device is officially certified as class IIA under the medical directive 93/42/EEC.

High frequency ultrasound scanning

The scanner (Figure 2) used to evaluate wound healing in this study was operated at a frequency of 20MHz (Episcan, Longport Inc). This frequency gives an axial resolution of 65µm.

Ultrasound scan images of three areas were taken on each patient




Figure 2. Ultrasound scanner.



Figure 1b. The Accel-Heal® unit.

(Figure 3). Region 1 was the centre of the wound, region 2 the periwound tissue and region 3 the intact adjacent skin. The latter was taken to establish the subject's normal skin condition. Several images were taken of each area to get a representative value of the tissue (Figure 4).

Scan analysis

Two aspects of the ultrasound scans were analysed.

Pixel distribution in the wound bed

Each scan of the wound bed was analysed using a form of pixel distribution analysis whereby pixels below a certain intensity are classed as low echogenic pixels (LEP). The ratio of LEPs to total pixel count (TP) has been shown to reflect changes in dermal water content (Kerr et al, 2006; Quintavalle et al, 2006). Using this technique, it was possible to get a quantitative assessment of the level of oedema present in the wound.

Periwound skin oedema

Using ultrasound, the width of the zone of oedema collecting beneath the epidermis of the intact periwound skin could be imaged and measured. The zone width was expressed as a percentage of the initial width.

Statistical analysis

The data fell into a paired sample t-test format, as paired readings are present for individual patients. All calculations were done using Excel.

Results

During the standard treatment period of four weeks before applying the Accel-Heal device, 54% of patients examined showed signs of healing and

were, therefore, excluded from the evaluation. Recruitment of subjects continued until 22 subjects from the initial assessment had VLU's that were classified as non-healing.

The subjects mean age was 69.2 ± 11.4 years, 62% of subjects were female. The mean duration of the VLU before the start of the evaluation was 2.0 ± 2.2 years.

At the end of visit five, 95% of the subjects' wounds had improved, with 38% healing to closure. The mean number of nurse visits with Accel-Heal was 35.9, over a period of 16 weeks, compared with the average number of nurse visits before the trial.

Pain scores before starting Accel-Heal treatment were an average of 5.3. At the end of the evaluation, mean pain levels had decreased to 1.6, a reduction of 69.8%.

Exudate levels before starting the evaluation averaged 5.8 on a score of 1 to 10, which reduced to a mean of 2.8.

Ultrasound assessment demonstrated a statistically significant acceleration of wound healing in 95% of the subjects.

Figure 5 shows the rate of healing over a maximum of 20 weeks, with

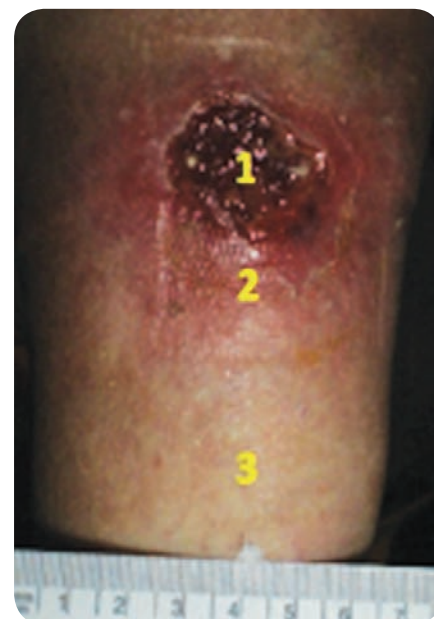

Figure 3. Wound area indicating regions scanned.

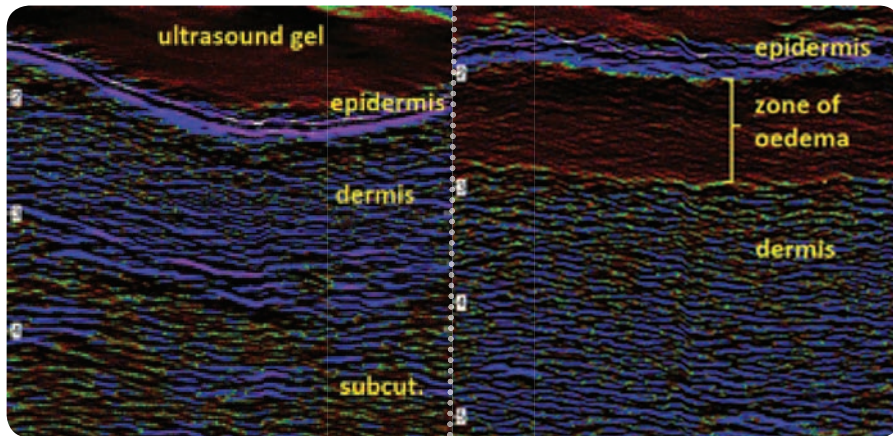


Figure 4. Example images showing typical ultrasound scans through a patient's normal uninjured skin, peri-wound skin and venous leg ulcer.

the purple line indicating that wounds with a cross-sectional area of less than 15cm² healed to closure within 13–19 weeks. The blue line outlines the rate of healing in wounds larger than 20cm². The similar shape of both graphs in the initial weeks of exposure to Accel-Heal suggests that had the treatment been applied for longer in the larger wounds, they too would have healed.

Discussion

As no control group was used in this evaluation, the strength of the results may be considered limited. However, within wound care, controlled studies are extremely difficult due to the limitations of inclusion/exclusion criteria and the differences both in the pathology of wounds and the comorbidities of patients (Rayner et al, 2009).

Yarkony (1994) reported that although many studies have been published on the effects of ES on the wound healing process, many of them had a poor sample size or were poorly controlled. In the authors' opinion, this is undoubtedly due to difficulties associated with undertaking controlled studies in wound care. The Cochrane collaboration rarely reports well on any study in wound care. However, the fact that each of these wounds were classified as non-healing before the evaluation, which was confirmed by ultrasound, and that 95% of them responded to ES, is an interesting finding. Figure 6 shows a typical VLU from the study that healed to closure.

In the authors' opinion, mechanical treatment modalities appear to be the way forward in the field of wound care. Many are modern adaptations of historic treatments, such as galvanic electrical

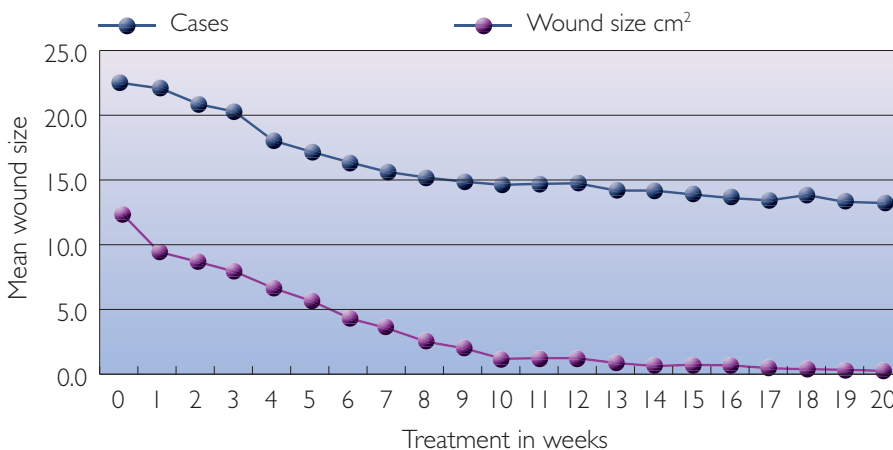


Figure 5: Rate of healing over 20 weeks. Blue line indicates wounds with a cross-sectional area less than 15cm² that healed to closure within thirteen to nineteen weeks. Purple line outlines the rate of healing in wounds larger than 20cm².

stimulation (originally using electric eels). Electric stimulation has been present for almost 300 years (Simpson, 2004). In the last thirty years, multiple modalities of this treatment have emerged. A recommendation could be that ES is used in wounds that have failed to heal after using other forms of treatment. This recommendation would exclude the potential use of ES to prevent wounds from becoming static or chronic.

Conclusion

The wounds in this evaluation had received every chance to heal before the application of Accel-Heal, as the patients had been referred to TVCS for treatment by tissue viability specialists. The fact that 95% of these wounds responded following application of ES was significant.

Using a predictive healing model, this evaluation showed that wounds of less than 15cm² could be expected to heal to closure within an eight-week period. The progress of the larger VLUs suggested that the Accel-Heal treatment was not applied for long enough. This is highlighted in the shape of the graph in smaller and larger VLUs (Figure 5). The first part of the graph of all the wounds showed a similar downward curve, with the wounds having an immediate healing response to the Accel-Heal treatment. However, the wounds less than 15cm² healed to closure, while the healing rate of the larger wounds slowed after the initial response. It was concluded in the health economist's report that Accel-Heal treatment should be applied until wounds have reduced by 50%.

Delays in healing chronic wounds is often a challenge for healthcare professionals and costly to the NHS. The clinical implications of this evaluation should be considered, as any reduction in treatment time will produce a corresponding reduction in cost and an increase in patient quality of life. Additionally, overcoming the effects of lengthy or treatment-resistant wound healing will allow time for nurses to address other health-related issues that are such a vital part of their role, such as preventative and proactive strategies for dealing with venous leg ulcers. **WUK**

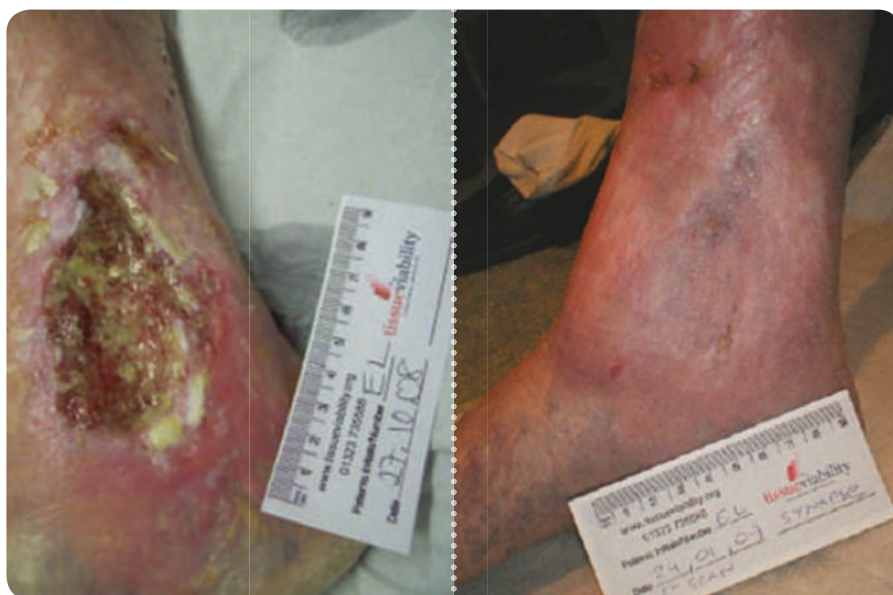

Figure 6. A typical VLU from the study that healed to closure in 89 days.

References

- Balakatounis KC, Angoules AG (2008) Low-intensity electrical stimulation in wound healing: review of the efficacy of externally applied currents resembling the current of injury *Eplasty* 8: e28
- Bayat M, Asgari-Moghadam Z, Maroufi M, Rezaie F-S, Rakhshan M (2006) Experimental wound healing using microamperage electrical stimulation in rabbits. *J Rehab Res Dev* 43(2): 219–26
- Bogie KM, Reger SI, Levine SP, Sahgal V (2000) Electrical stimulation for pressure sore prevention and wound healing. *Appl Res* 12: 50–66
- Chen L, Dyson M, Rymer J, et al (2001) The use of high frequency diagnostic ultrasound to investigate the effect of HRT on skin thickness. *Skin Res Tech* 7(2): 95–7
- Gagnier KA, et al (1988) The effects of electrical stimulation on cutaneous oxygen supply in paraplegics. *Phys Ther* 68(5): 835–9
- Jaffe LF, Venable JW (1984) As the wound heals, the current of injury is also reduced. Electric fields and wound healing. *Clin Dermatol* 2(3): 34–44
- Junger M, et al (1997) Treatment of venous ulcers with low-frequency pulsed current (Dermapulse): effect on cutaneous microcirculation (German). *Hautarzt* 48(12): 879–903
- Karba RI, Semrov D, Vodovnik L, Benko H, Savrin RDC (1997) Electrical stimulation for chronic wound healing enhancement. *Bioelectrochemistry Bioenergetics* 43: 271–7
- Kerr A, Young S, Hampton S (2006) Has packing sinus wounds become a ritualistic practice? *Br J Nurs* 15(19): S27–S30
- Kloth LC (2002) How to use electrical stimulation for wound healing. *Nursing* 32(12): 17
- Kloth LC, McCulloch JM (1996) Promotion of wound healing with electrical stimulation. *Adv Skin Wound Care* 9(5): 42–5
- Mirpuri N, Young SR (2001) The use of diagnostic ultrasound to assess the skin changes that occur during normal and hypertensive pregnancies. *Skin Res Tech* 7: 63–9
- Mohr T, Akers TM, Landry RL (1987) Effect of high voltage stimulation on edema reduction in the rat hind limb. *Phys Ther* 67: 1703–8
- O'Meara S, Cullum NA, Nelson EA (2009) Compression for venous leg ulcers. *Cochrane Database of Systematic Reviews* 2009, Issue 1. Art. No.: CD000265
- Peters EJG, et al (1998) The benefit of electrical stimulation to enhance perfusion in persons with diabetes mellitus. *J Foot Ankle Surg* 37(5): 396–400
- Posnett J, Franks PJ (2008) The burden of chronic wounds in the UK. *Nurs Times* 104(3): 44–5
- Quintavalle P, Lyder CH, Mertz PJ, et al (2006) Use of high-resolution, high frequency diagnostic ultrasound to investigate the pathogenesis of pressure ulcer development. *Adv Skin Wound Care* 19(9): 498–505
- Rayner R, Carville K, Keaton J, Prentice J, Santamaria N (2009) Leg ulcers: atypical presentations and associated comorbidities. *Wound Practice Res* 17(4): 168–185. Available online at: www.health.wa.gov.au/woundswest/docs/WPR_Nov09_Atypical_Leg_Ulcers.pdf
- Reed BV (1988) Effect of high voltage pulsed electrical stimulation on microvascular permeability to plasma protein: a possible mechanism in minimizing edema. *Phys Ther* 68: 491–5
- Rosenblum J (2009) Electrical stimulation: can it help facilitate wound closure? *Podiatry Today* 22. Available online at: www.podiatrytoday.com/electrical-stimulation-can-it-help-facilitate-wound-closure
- Sussman C, Byl N (1998) Electrical stimulation for wound healing. In: Sussman C, Bates-Jensen BM, eds. *Wound Care Collaborative Practice Manual for Physical Therapists and Nurses*. Aspen Publishers: chap 16
- Yarkony GM (1994) Pressure ulcers: A review. *Arch Phys Med Rehabil* 75(8): 908–17
- Young SR, Ballard K (2001) Wound Assessment: Diagnostic and assessment applications – Part 2. In: *Electrotherapy-Evidence based practice*. Churchill-Livingstone, London: 308–12
- Young S, Bolton PA, Downie J (2008) Use of high-frequency ultrasound in the assessment of injectable dermal fillers. *Skin Res Tech* 1(14): 1–4
- Simpson BA (2004) *Electrical Stimulation and the Relief of Pain*. Elsevier

Key points

- ▶ Electrical stimulation (ES) is the use of an electrical current to transfer energy to a wound.
- ▶ Accel-Heal™ (Synapse) uses a specific proprietary sequence of micro-current electrical pulses designed to interact with biological processes that have become dormant within a chronic non-healing wound
- ▶ Delays in healing chronic wounds is often a challenge for healthcare professionals and costly to the NHS.
- ▶ In the authors' opinion, mechanical treatment modalities appear to be the way forward in the field of wound care.